Vet Pathol 29:301–307 (1992)

Brain Lesions of Naturally Occurring Pregnancy Toxemia of Sheep

M. JEFFREY AND R. J. HIGGINS

Lasswade Veterinary Laboratory, Bush Estate, Penicuik, Scotland (MJ); and
Thirsk Veterinary Investigation Centre, Station Road, Thirsk, Yorkshire, England (RJH)

Abstract. The neuropathology and biochemical features of 17 sheep with clinical signs and gross necropsy features of naturally occurring pregnancy toxemia were retrospectively evaluated. The sheep ranged in age from 3 to 6 years and were of seven different breeds and three breed crosses. Thirteen sheep (case Nos. 1–4, 6–9, 11–14, 16) showed astrocytic nuclear swelling, hypertrophy and proliferation, and cerebrocortical neuronal necrosis. Seven of these sheep had Purkinje cell necrosis (case Nos. 2, 3, 6, 11, 12, 14, 16), and seven had vacuolation of cerebral and cerebellar sub-cortical white matter (case Nos. 1–4, 9, 12, 13). The neuropathologic features were similar to those of naturally occurring hypoglycemia of human beings and experimentally induced hypoglycemia of primates and the rat. The lesions seen in the sheep studied may have been caused by cerebral hypoglycemia, but data for blood or cerebral glucose concentrations were not available.

Key words: Astrocytosis; brain; hypoglycemia; neuronal necrosis; pregnancy toxemia; sheep.

Ovine pregnancy toxemia or "twin-lamb" disease occurs in the latter part of pregnancy in sheep, typically in ewes with multiple fetuses, and is characterized by anorexia and neurologic signs of motor weakness, amaurosis, and mental dullness.[9] It may occur spontaneously or may be induced by dietary deficiency. The disease is associated with the high calorific requirements of pregnant sheep. Pregnancy toxemia may occur following a relative deficiency of available carbohydrate that leads to a drain on oxaloacetate and its precursors in an effort to maintain blood glucose concentrations.[9] Toxemia can usually be prevented by adequate supplementary feeding in late pregnancy.[9] Clinical pathologic studies show consistent elevation of blood ketones and glucocorticoids and, in the early part of the disease, decreased blood glucose.[13] Decreased blood glucose concentration is, however, an incomplete explanation for this complex metabolic disease; the major precipitating cause of the condition may be an adrenal response to environmental stress.[9] Because there is a relationship between the depth of hypoglycemia and the severity of nervous derangement, McClymont and Setchell[14–16] proposed that clinical signs are the result of hypoglycemic encephalopathy. A recent review reports that no observer has been able to detect microscopic or gross changes in the brain of affected sheep.[9]

This report describes a retrospective survey of the histologic findings of 17 cases of pregnancy toxemia, in which 13 brains showed histologic evidence of ischemic-type neuronal degeneration of the cerebral cortex.

Materials and Methods

Animals

The brains of 17 female sheep with clinical neurologic signs, gross postmortem features, and biochemical findings suggestive of pregnancy toxemia were available for histologic examination. Sheep were of various breeds and breed crosses, including Suffolk, Suffolk cross, Mule, Masham, Charolais, and Swaledale. In the cases where age was recorded, the ewes were from 3 to 6 years old. Sheep were submitted to the Thirsk Veterinary Investigation Centre (Yorkshire, England) between 1983 and 1989, where they were euthanatized with intravenous pentobarbitone sodium or died in extremis. In each case, ante mortem clinical signs, usually of several days' duration, consisted of mental dullness, anorexia, weakness and whole body tremors, amaurosis, and progressive neurologic deficits that led to recumbency. Necropsy findings consistently included enlarged fatty livers and multiple late-term fetuses that were found in utero. Although complete details for each sheep were not available, appropriate testing within the group eliminated major differential diagnosis of neurologic disorders of adult sheep, including lead poisoning, cerebrocortical necrosis (syn. polioencephalomalacia), hypocalcemia, and hypomagnesemia (Table 1).

Biochemistry

All biochemical techniques were carried out according to standard Ministry of Agriculture, Fisheries and Food, Veterinary Investigation Service methods supported by a routine quality assurance program. Serum and aqueous humour calcium and magnesium concentrations were measured with either a Cecil spectrophotometer (Cecil Instruments, Cambridge, England) or Vitalab 100 Auto-analyzer (Vital Sci-

Table 1. Biochemical findings and frequency of brain lesions in 17 sheep with toxemia.

Sheep No.	Brain Lesions	Live (L) or Dead (D)	TTP* (%)	Liver Lead (μ/mol/kg)	Acetone (mg%)	Serum		
						BHB† (mM/liter)	Calcium (mM/liter)	Magnesium (mM/liter)
1	+	L	43			6.66	2.56	0.81
2	+	L			50	5.90	3.21	0.95
3	+	D						
4	+	D			‖		1.4§	1.1§
5	0	L	36.3			2.55	1.8	1.5
6	+	D				3.5§	2.6§	0.88§
7	+	L	61.8	10	30	8.65	2.37	0.35
8	+	D		44	‖			1.09§
9	+	D		46	‖			1.2
10	0	L		5		1.91	2.62	0.74
11	+	L	38.4		30	2.38		
12	+	L	42			2.87	2.48	0.70
13#	+	L					n¶	n¶
14	+	L			30		2.0	0.70
15	0	L				4.41	1.97	0.95
16	+	D						1.26§
17	0	D					1.88§	1.72§
Normal values			12–96	0–50	0–10	0–1.2	2–3	0.7–1.3

* Thiamine pyrophosphate effect.
† Beta-hydroxybutyrate.
§ Values obtained by examination of aqueous humour.
‖ Elevated value, exact value not known.
\# This sheep had low blood glucose concentration, exact value not known.
¶ Normal value, exact value not known.

Table 2. Occurrence, severity, and distribution of lesions in brains of 17 toxemic sheep.

Sheep No.	Cerebrocortical Lesions*			Purkinje Cell Necrosis
	Frontal	Parietal	Occipital	
1	++	++	++	Absent
2	+++	0	0	Present
3	+++	+++	+++	Present
4	+	+++	++	Absent
5	0	0	0	Absent
6	++	+++	+++	Present
7	++	+	+++	Absent
8	++	+++	+++	Absent
9	+	++	+	Absent
10	0	0	0	Absent
11	++	NA†	NA	Present
12	+++	NA	NA	Present
13	+++	NA	NA	Absent
14	NA	++	NA	Present
15	0	NA	NA	Absent
16	++	NA	NA	Present
17	NA	0	NA	Absent

* 0 = no significant lesions; + = sparse necrosis of individual neurons; ++ = necrosis of neurons in outer neuron layers of cortical gray matter; +++ = necrosis of neurons in all cortical neuron layers.
† NA = not available for examination.

entific, Sussex, England) using commercially available kits. Beta-hydroxybutyrate estimation of serum was based on the method of Davies.[7] Thiamine pyrophosphate effect was determined in whole blood as described by Jackman.[11] Liver tissue lead levels were read using atomic absorption spectrophotometry.

Histology

Brains and livers were fixed in 10% neutral phosphate-buffered formalin. Following fixation, the brain was examined under 360-nm wavelength fluorescent light. The cerebellum was then removed by sectioning through the cerebellar peduncles, and the brain was sectioned in a standardized fashion. Tissue slices of brain included medulla at the level of the obex and at the cerebellar peduncles, midbrain at the level of the rostral colliculi, occipital cerebrum and hippocampus, parietal cerebrum and thalamus at the level of the optic chiasma, frontal cerebrum and striatum at the level of the head of the caudate nucleus, and sagittal cerebellum. Not all sites of the cerebrum from each sheep were available for histologic examination (Table 2). Tissue slices were dehydrated and embedded in paraffin wax (Miles Tissue Tec II embedding wax, Elkhart, IN), sectioned at 5 μm, and stained with hematoxylin and eosin, Bodian's stain for axons, cresyl-fast violet, or, to aid the recognition of ischemic neuronal change, by the cresyl-fast violet/acid fuchsin technique.[4] Frozen samples of fixed liver were also stained by the Oil-Red-O method. Selected sections were stained for glial fibrillary acidic protein by the peroxidase–anti-peroxidase and immunohis-

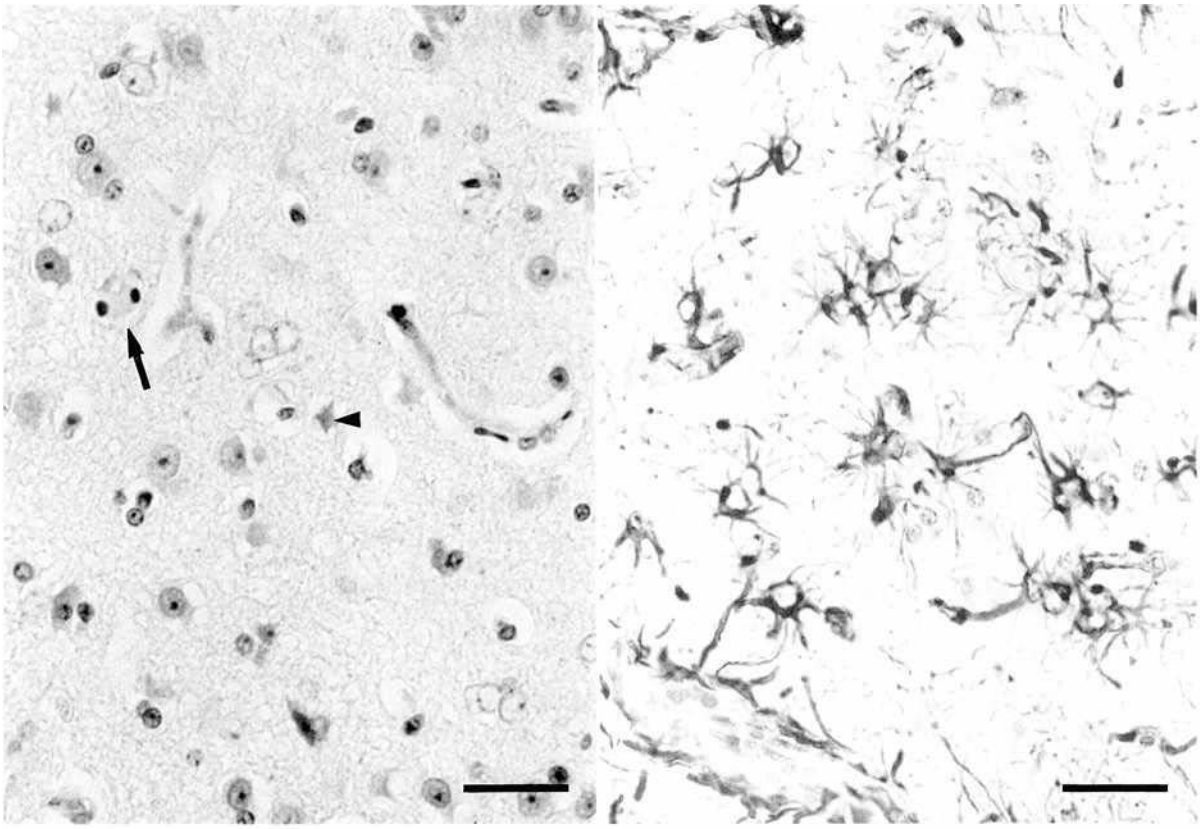

Fig. 1. Cerebral cortex; sheep No. 12. The cortex has swollen astrocytic nuclei, with rarefaction of nuclear chromatin and finely vacuolated neuropil. A mitotic figure in a glial cell (arrow) and a neuron with cytoplasmic eosinophilia (arrowhead) are also present. HE. Bar = 20 μm.

Fig. 2. Cerebral cortex; sheep No. 7. The cortex shows an increased number of astrocytes; some are clustered in small groups. Perikaryonal and major processes show increased expression of glial fibrillary acid protein. Peroxidase anti-peroxidase for glial fibrillary acidic protein. Bar = 20 μm.

tochemical technique according to methods previously published.[12] The distribution and morphologic findings of glial fibrillary acid protein were compared with those previously described for the normal sheep.[12]

Results

A summary of the pathologic and biochemical results is shown in Tables 1 and 2.

All sheep were routinely examined at necropsy for any evidence of recent excess cereal ingestion, leading to ruminal acidosis with negative results. Seven sheep (case Nos. 2, 4, 6–8, 14, 18) had empty rumens.

No significant gross brain lesions were seen, and there was no evidence of cortical autofluorescence on examination with ultraviolet light. Examination of liver sections of nine sheep (case Nos. 2, 3, 5–7, 15–18) stained by Oil-Red-O confirmed severe diffuse fat infiltration.

The frequency and distribution of cerebrocortical and cerebellar cortical lesions are shown in Table 2. Thirteen brains showed mild to moderate cerebrocortical astrocytic nuclear swelling with rarefaction of nuclear chromatin (Fig. 1) and mild to moderate multifocal perivascular and perineuronal tissue spaces. These changes were seen in all cerebral cortices. When compared with type I astrocytes of normal sheep brain, cerebrocortical astrocytes showed increased staining for glial fibrillary acidic protein in perikarya and major cell processes (Fig. 2). Groups of astrocytic nuclei (Fig. 2), suggestive of astrocyte proliferation, rare mitotic figures, and an increased density of astrocytes, were also present. Both individual neurons and small groups of these cells, occasionally sufficient in extent to form a laminar pattern, showed perikaryal and nuclear shrinkage, both often becoming triangular in form (Fig. 3), as well as marked cytoplasmic and nucleolar eosinophilia. The nuclei and cytoplasm of such cells stained bright blue or mauve with cresyl-fast violet; degenerate neurons were bright red with acid fuchsin/cresyl-fast violet preparations. Sparse neurons with encrustations were also seen. These changes were interpreted as ischemic-type neuronal degeneration with

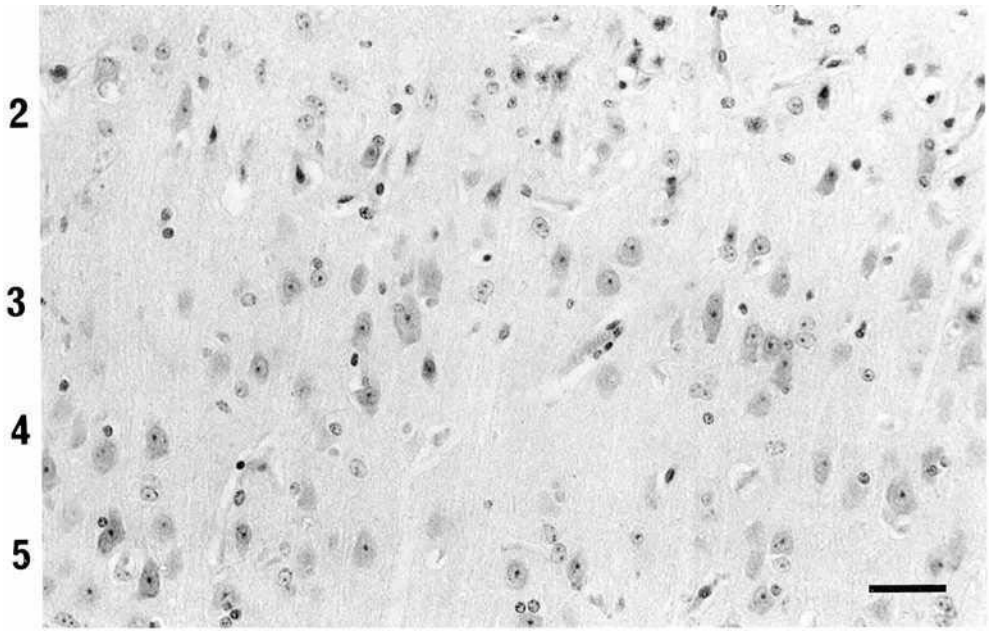

Fig. 3. Cerebral cortex; sheep No. 4. The cortex has numerous neurons with shrunken cytoplasm and has triangular nuclei in pyramidal neurons of layer 2. Neurons in layers 3–5 are not affected by this change. Numbers to the left of the Figure indicate approximate cytologic layer of the cerebral cortex. Bar = 30 μm.

astrocytic swelling (without prejudice concerning the cause of ischemia). Such changes involved all cortical regions, with more severe lesions present in the occipital and parietal regions of some brains (Table 2). Neurons of cerebrocortical layers 2 and 3 were sometimes preferentially affected, whereas neurons in the deeper cortical layers were spared. The cingulate, sylvian, and supra-sylvian gyri, at all cortical levels, were usually the most severely affected parts of the cortex.

In seven brains (case Nos. 1–4, 9, 12, 13), there was mild vacuolation of white matter. The vacuolation, which was interpreted as edema, was most prominent in the gyri of cerebral cortex and also in the cerebellar white matter (Fig. 4). Sparse Purkinje cell necrosis was also seen in the cerebellum, most notably in vermis lobules nine and ten (Fig. 5). Multifocal meningeal and perivascular cellular infiltration comprised of lymphocytes, macrophages, and sparse polymorphs was also present. Although always mild, the magnitude of these meningeal cellular infiltrates corresponded to the degree and distribution of cerebral or cerebellar cortical necrosis and edema.

Discussion

Previous studies of naturally occurring and experimental ovine pregnancy toxemia do not record morphologic evidence of an encephalopathy in toxemic sheep.[9] Because pregnancy toxemia can usually be diagnosed on the basis of clinical signs and gross pathologic features, however, histologic examination of the brain is rarely undertaken. Nevertheless, the clinical signs and the gross and microscopic pathologic findings of the cases described in this report support a diagnosis of pregnancy toxemia and are associated with histologic features of neuronal necrosis and astrocytic nuclear swelling, hypertrophy, and proliferation.

In sheep submitted live, energy status was assessed biochemically by measurement of serum beta-hydroxybutyrate and ketones rather than plasma glucose, because plasma glucose is a relatively unstable blood constituent. Although these three parameters measure different indices and are not exactly comparable, elevated beta-hydroxybutyrate values, hyperketonemia, and hypoglycemia are all features at some stages of pregnancy toxemia in sheep.[13] Beta-hydroxybutyrate values in well-fed ewes are usually below 0.5 mM; ketonuria is usually evident when levels exceed 0.7 mM. Ewes with clinical signs of pregnancy toxemia have serum ketone body (aceto-acetate plus beta-hydroxybutyrate) concentrations in excess of 3.0 mM. Biochemical data were therefore typical of pregnancy toxemia and by extrapolation the ewes probably experienced periods of hypoglycemia. Blood glucose concentrations between 20 and 40 mg/dl or 1.2 and 2.2 mM are common in pregnancy toxemia, although comatose animals may show terminal hyperglycemia, especially associated with fetal death.[13]

Ischemia, hypoglycemia, and epilepsy are different primary disorders affecting the brain, but they produce injury that gives rise to similar if not identical brain

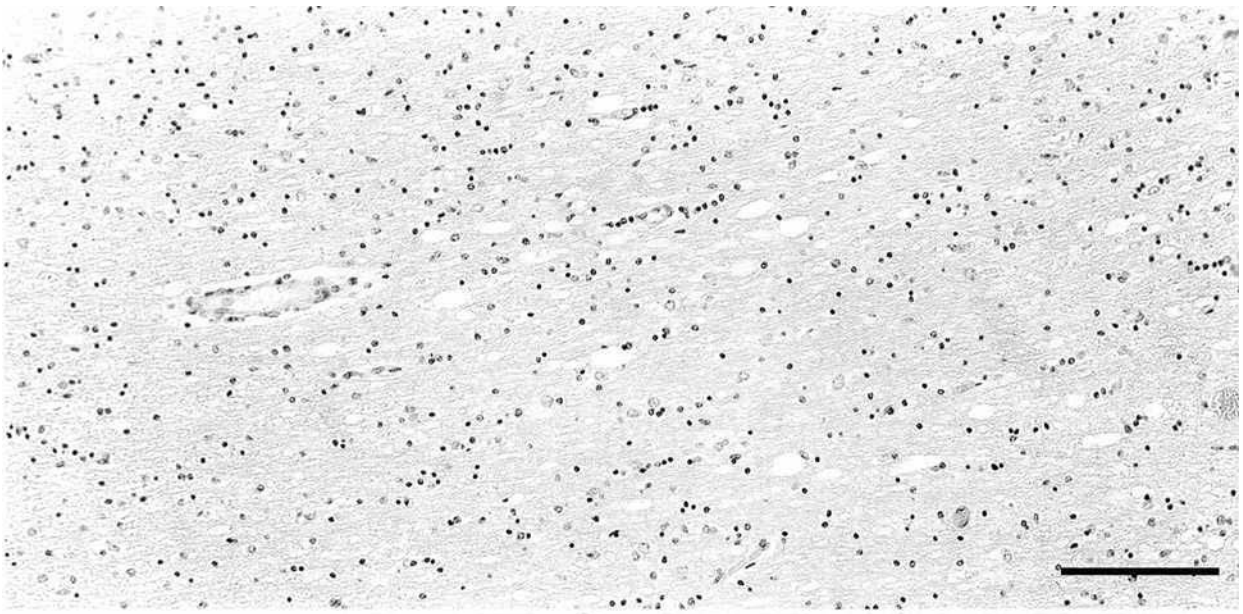

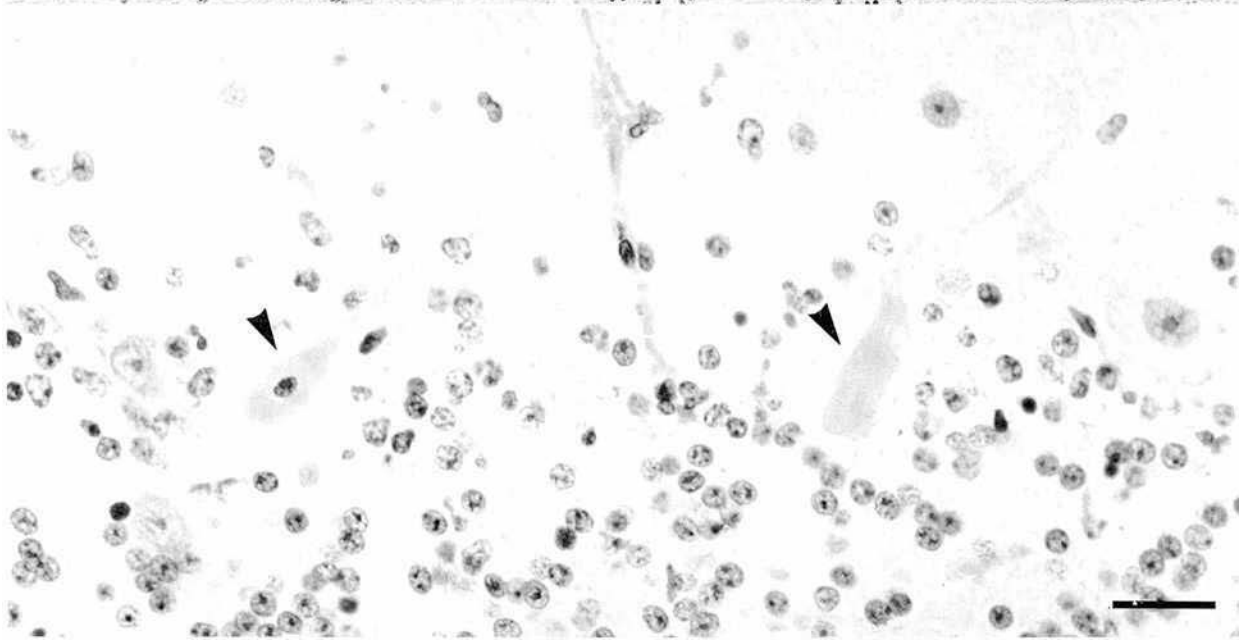

Fig. 4. Cerebral subcortical white matter; sheep No. 6. There is sparse diffuse vacuolation. HE. Bar = 150 μm.
Fig. 5. Cerebellar cortex; sheep No. 6. Two Purkinje cells (arrowheads) have marked cytoplasmic eosinophilia. One of these has a pyknotic nucleus. HE. Bar = 30 μm.

damage.[3] The term "ischemic cell change" has been applied, therefore, indiscriminately to injured neurons in all three disorders.[3] Although each of these disorders affects energy metabolism by arresting or impeding cellular energy production (ischemia and hypoglycemia) or pathologically enhancing energy consumption (epilepsy), there are differences in the underlying neurochemical changes, neuronal revival times, lesion topography, and the time course of neuronal death in both natural and experimental models of these disorders.[2,3] Historic data ruled out hypoxia–ischemia or seizures as a cause of neuronal damage in the sheep investigated in the present study.

One of the features of experimental hypoglycemia is the preferential necrosis of neurons in the superficial laminae of the cerebral cortex.[3] In contrast, ischemia causes necrosis of neurons in the middle cortical laminae.[3] Neuronal necrosis was observed principally in superficial cortical layers in the brains of sheep examined in this study; however, the neuropathology of hypoglycemia in sheep has not been described, and data relating to blood and cerebral glucose levels in the

study sheep were not available. Experimental cerebral ischemia of sheep causes neuronal necrosis at so-called "selectively vulnerable" sites[19] (including pyramidal neurons of mid-cortical laminae) similar to that in human beings and rodents.[1,5] Clinical histories suggesting previous epileptiform seizure activity were not reported for these sheep.

Agardh and coworkers[2] found two types of neuronal change in insulin-induced hypoglycemia in the rat. "Type-1" injury was characterized by angulated, darkly stained neurons with perineuronal vacuolation, mainly affecting neurons of cortical layer 3. "Type-2" injured neurons, mainly in layers 5–6, were slightly swollen with vacuolation or clearing of peripheral cytoplasm and were considered characteristic of hypoglycemia. No nuclear changes were seen in this type of neuronal injury. These changes were considered different from those of anoxia–ischemia.[1,5] "Type-1" neurons, although similar in other respects to neurons seen in anoxia–ischemia, do not show cytoplasmic vacuolation.[1,5] These features are characteristic of incomplete or transient anoxia–ischemia[5] and therefore are not often seen in brains obtained from field case necropsy material.[1] We did not observe "type-2" neuronal changes in toxemic sheep although some areas of cortex in some sheep did show neuronal degeneration involving all cortical layers. "Type-2" neuronal change is also a transient pathologic feature that disappeared when glucose levels were restored.[2]

Not all sheep with pregnancy toxemia in this study (as well as others for which data are not presented) showed histologic evidence of astrocyte nuclear swelling, hypertrophy, and neuronal necrosis. Some sheep showed no significant histologic lesions. The clinical pathologic findings of pregnancy toxemia, in addition to disorders of glucose metabolism, include raised glucocorticoid concentration.[9] Elevation of glucocorticoids may be due to an increase in adrenal production or due to poor hydrogenation and conjugation by the damaged liver. Previous studies have shown that sustained exposure to elevated glucocorticoids is toxic to neurons and may compromise the capacity of neurons to survive a variety of metabolic insults.[18] Elevated glucocorticoids potentiate ischemic neuronal injury.[18] Sustained raised glucocorticoid levels may potentiate or contribute to neuronal necrosis and should be considered as a possible reason for the occurrence of lesions in some toxemic sheep and not in others.

Further evidence of pathologic findings that are secondary to impaired liver function and that lead to increased circulating toxic metabolites is suggested by subcortical white matter vacuolation. These vacuoles are morphologically consistent with a diagnosis of myelin splitting and intramyelinic edema,[6] such as is commonly found in hepatic encephalopathy.[10]

Astrocytic hypertrophy is also a well-recognized feature of hepatic encephalopathy.[8] Experimental administration of methionine sulfoximine (an inhibitor of the enzyme glutamine synthetase, which detoxifies ammonia in the central nervous system) has been reported to cause increased expression of glial fibrillary acidic protein,[20] but ammonia itself may decrease glial fibrillary acidic protein in astrocytes.[17]

Astrocytic hypertrophy and proliferation and increased glial fibrillary acidic protein expression were prominent features in our cases. Because, however, hypertrophy, proliferation, and increased fibrillary protein expression of these glia are common responses to a variety of infectious, metabolic, and traumatic insults in the central nervous system, such changes are of doubtful specificity.

This study is the first to show that lesions of neuronal necrosis occur in some cases of pregnancy toxemia. Although measurements of cerebral glucose status were not available, hypoglycemia is a recognized feature of pregnancy toxemia.[9] We therefore suggest that because the lesions found in these sheep are morphologically similar to the lesions of naturally occurring hypoglycemia of human beings[5] and experimental hypoglycemia of primates and rats,[3] the sheep lesions may also indicate a functional cerebral glucose deficit. The relationship between the severity of neurologic symptoms and depth of hypoglycemia[14–16] provides additional clinical evidence of a hypoglycemic encephalopathy. Sheep with pregnancy toxemia rarely respond, however, to the administration of glucose, perhaps because in the later stages of disease they may enter renal failure, become dehydrated, and have an altered acid–base status.

A retrospective study of the pathologic findings of field cases of pregnancy toxemia cannot provide information pertaining to the possible occurrence, duration, and severity of important neurochemical parameters, including levels of cerebral glucose, lactic acid, ketones, corticosteroids, and toxic liver metabolites. Further experimental studies are therefore required to determine the pathogenesis of the cerebrocortical lesions in sheep with pregnancy toxemia.

References

1 Adams JH, Brierly JB, Connor RCR, Triep CS: The effects of systemic hypotension upon the human brain. Clinical and neuropathological observations in 11 cases. Brain **89**:235–268, 1966

2 Agardh CD, Kalimo H, Olsson Y, Siesjo BK: Hypoglycemic brain injury. I. Metabolic and light microscopic findings in rat cerebral cortex during profound insulin-induced hypoglycemia and in the recovery period following glucose administation. Acta Neuropathol (Berl) **50**:31–41, 1980

3 Auer RN, Siesjo BK: Biological differences between ischemia, hypoglycaemia and epilepsy. Ann Neurol **24**: 699–707, 1988
4 Auer RN, Wieloch T, Olsson Y, Siesjo BK: The distribution of hypoglycemic brain damage. Acta Neuropathol (Berl) **64**:177–191, 1984
5 Brierly JB, Graham DI: Hypoxia and vascular disorders of the central nervous system. *In:* Greenfield's Neuropathology, ed. Hume Adams J, Corsellis JAN, and Duchen LW, 4th ed., pp. 125–207. Edward Arnold, London, England, 1984
6 Cho DY, Leipold HW: Experimental spongy degeneration in calves. Acta Neuropathol (Berl) **39**:115–117, 1977
7 Davies GW: A method of estimating beta-hydroxy-butyrate. Medium **12**:61–66, 1979
8 Duchen LW, Jacobs JM: Nutritional deficiencies and metabolic disorders. *In:* Greenfield's Neuropathology, ed. Hume Adams J, Corsellis JAN, and Duchen LW, 4th ed., pp. 596–603. Edward Arnold, London, England, 1984
9 Ford EJH: Pregnancy toxaemia. *In:* Diseases of Sheep, ed. Martin WB, pp. 147–150. Blackwell Scientific Publications, Oxford, England, 1983
10 Hooper PT: Spongy degeneration in the central nervous system of domestic animals. Part 1: Morphology. Acta Neuropathol (Berl) **31**:325–334, 1975
11 Jackman R: The diagnosis of CCN and thiamine deficiency in ruminants. Vet Ann **25**:71–77, 1985
12 Jeffrey M, Wells GAH, Bridges AW: An immunohistochemical study of the topography and cellular localization of three neural proteins in the sheep nervous system. J Comp Pathol **103**:23–35, 1990
13 Marteniuk JV, Herdt TH: Metabolic diseases of ruminant livestock. Vet Clin North Am (Food Anim Pract) **4**:307–316, 1988
14 McClymont GL, Setchell BP: Ovine pregnancy toxaemia. II. Experimental therapy with glycerol and glucose. Aust Vet J **31**:170–174, 1955
15 McClymont GL, Setchell BP: Ovine pregnancy toxaemia. III. Further evidence of the correlation of the depth of hypoglycaemia and induction of the symptoms. Aust Vet J **32**:22–25, 1956a
16 McClymont GL, Setchell BP: Ovine pregnancy toxaemia. IV. Insulin induced hypoglycaemic encephalopathy in the sheep and its implications as regards the pathogenesis of the disease. Aust Vet J **32**:97–109, 1956b
17 Norenberg MD, Neary JT, Norenberg L-OB, McCarthy M: Ammonia induced decrease in glial fibrillary acidic protein in cultured astrocytes. J Neuropathol Exp Neurol **49**:399–405, 1990
18 Sapolsky RM, Pulsinelli WA: Glucocorticoids potentiate ischemic injury to neurons: therapeutic implications. Science **229**:1397–1400, 1985
19 Terlecki S, Baldwin BA, Bell FR: Experimental cerebral ischaemia in sheep. Neuropathology and clinical effects. Acta Neuropathol (Berl) **7**:185–200, 1967
20 Yamamoto T, Iwasaki Y, Sato Y, Yamamoto H, Konno H: Astrocytic pathology of methionine sulfoximine-induced encephalopathy. Acta Neuropathol (Berl) **77**:357–369, 1989

Request reprints from Dr. M. Jeffrey, Lasswade Veterinary Laboratory, Bush Estate, Penicuik, Midlothian EH26 0SA, Scotland (UK).